

## Original Article

# Prevalence of Paranasal Sinus Abnormality on CT Brain and Its Clinical Correlation to Chronic Rhinosinusitis in Adult Patients at Thammasat University Hospital

Suchada Boonlue, Nithita Sattaratpajit\*

## Abstract

**Introduction:** To investigate the prevalence of incidental findings which were suspected as rhinosinusitis on computed tomography (CT) imaging of the brain and identify if there are any clinical correlations between CT abnormalities and patients' symptoms.

**Methods:** A descriptive and cross-sectional study of total 104 subjects who underwent CT brain for non-paranasal sinus related conditions. The CT findings were analyzed based on the Lund-Mackay scores by two blinded reviewers and the patients were divided into two groups according to their Lund-Mackay scores to compare differences between patients' symptoms. The 22-question Sino-Nasal Outcome Test (SNOT-22) was completed if chronic rhinosinusitis symptoms were suggested.

**Results:** The prevalence of incidental paranasal sinus abnormality was 10.6%. The most common sinus abnormality was the maxillary sinus (41.3%), followed by anterior ethmoid sinus (19.2%) and posterior ethmoid sinus (15.4%). Patients' symptoms were not found to be significantly different between groups of normal and abnormal Lund-Mackay scores. Additionally, there was no significant correlation between Lund-Mackay scores and the SNOT-22 scores among the chronic rhinosinusitis patients ( $r = -0.18$ ,  $P = 0.657$ ).

**Conclusions:** The prevalence of incidental paranasal sinus abnormality was 10.6%. Incidental CT findings suggestive of rhinosinusitis may not correlate with symptoms.

**Keywords:** Incidental findings, Computed tomography, Paranasal sinuses, Sinusitis

Received: 28 May 2021

Revised: 14 July 2021

Accepted: 19 July 2021

Department of Otolaryngology-Head and Neck Surgery, Faculty of Medicine, Thammasat University, Pathum Thani 12120, Thailand

\*Corresponding author: Nithita Sattaratpajit, Department of Otolaryngology-Head and Neck Surgery, Faculty of Medicine, Thammasat University, Pathum Thani 12120, Thailand Email: nithita.s@gmail.com

## Introduction

Computed tomography (CT) is increasingly used for accurate diagnosis and improved treatment. The prevalence of incidental sinus abnormalities on CT ranges from 15 to 43%.<sup>1,2</sup> This range is partially due to variations in study methodology, subjects' characteristics, and definitions of abnormalities. The detection of incidental findings unrelated to the purpose of imaging can also increase overdiagnosis and patients' anxiety.<sup>3</sup> The relationship between abnormal radiologic findings of paranasal sinuses such as mucosal thickening, fluid levels, and total opacification with rhinosinusitis symptoms, which can be observed in patients with colds, influenza, rhinitis and allergic asthma often remains uncertain.<sup>4</sup> However, The European Position Paper on Rhinosinusitis and Nasal Polyps 2020 (EPOS) integrates symptomatic, endoscopic and radiographic criteria into the clinical definition of rhinosinusitis.<sup>5</sup>

Various CT-based staging systems on sinus abnormalities have been proposed and studied. The Lund-Mackay (LM) scoring system is simple, widely accepted and achieves high interobserver reliability.<sup>6,7</sup> Many studies have reported incidentally normal Lund-Mackay scores.<sup>8,9</sup> However, there is no standard cut-off point for abnormal LM scores. Nazri et al.<sup>1</sup> concluded that a LM score exceeding 3 was abnormal. In addition, 76% of the EPOS 2020 steering committee suggested that after failure of appropriate medical or surgical treatment of chronic rhinosinusitis (CRS) resulting in continued symptoms and abnormal endoscopy, CRS is clinically relevant when LM scores are 2 due to complete obstruction of one sinus and 72% of the committee suggested that CRS is clinically relevant when LM scores are 3.<sup>5</sup>

The 22-question Sino-Nasal Outcome Test (SNOT-22) is a widely used disease-specific questionnaire for chronic rhinosinusitis which has been translated into Thai language.<sup>10,11</sup> SNOT-22 is quite reliable, valid, and easy to use to distinguish between patients with and those without chronic rhinosinusitis.<sup>12</sup>

In this study, we aim to evaluate the prevalence of incidental sinus abnormalities on CT imaging of the brain for non-sinus related conditions using the Lund-Mackay scoring system and to assess the correlations of CT imaging

findings with sino-nasal symptoms and disease specific questionnaire based on SNOT-22.

## Methods

A descriptive cross-sectional study was conducted with 106 patients with non-sinus related diagnoses referred for CT imaging of the brain at Thammasat University Hospital from November 2020 to February 2021. The protocol was approved by the Human Research Ethics Committee of Thammasat University (MTU-EC-OL-0-194/63). Only patients  $\geq 18$  years old who had CT brain scans which could be completely visualized in all sinuses were included. Informed consents were obtained from all patients. Exclusion criteria included subjects with major head trauma (e.g., intracranial hemorrhage, skull fracture) in whom nonspecific sinus findings may have been due to acute bleeding, emergency conditions that required first aid (e.g., unconsciousness, cerebral hemorrhage, shock) and patients who refused to complete the questionnaire.

The patients were required to answer a standard questionnaire which included gender, age, underlying disease, indication for CT imaging of the brain, sino-nasal symptoms (e.g., nasal discharge, nasal obstruction or congestion, facial pain or pressure, decreased sense of smell), and history of previous sinus surgery. Patients were requested to complete the SNOT-22 if they were suspected of having chronic rhinosinusitis. Suspicion of CRS was based on clinical diagnostic criteria of EPOS 2020,<sup>5</sup> the presence for at least 12 weeks of at least 2 out of 4 symptoms (i.e., nasal blockage/obstruction, nasal discharge, facial pain/pressure, hyposmia/anosmia). The questionnaires were filled within 48 hours before or after CT imaging to ensure the highest chance of correlation with the current imaging findings.

The CT scans were performed using IQon Spectral CT (Philips Healthcare, Cleveland, OH, USA) and the images were reviewed electronically on a picture archiving and communication system (PACS). Each image was analyzed by two otorhinolaryngologists (blind and independent). Images were graded using the Lund-Mackay CT grading system and consensus Lund-Mackay scores (from the two reviewers) were given for each case.

The Lund-Mackay CT grading system involves scoring 6 bilateral areas of sinuses, each area (maxillary, anterior ethmoid, posterior ethmoid, frontal sphenoid sinus on right and left sides) was graded a score (0 for no abnormality, 1 for partial opacification, 2 for total opacification) and the ostiomeatal complex on each side was also graded a score (0 for not occluded, 2 for occluded). Thus, the total score ranges from 0 to 24.<sup>13</sup> A Lund-Mackay score less than 4 was classified as no CT abnormality and a score greater than or equal to 4 was classified as CT abnormality which was suspected sinusitis.<sup>14</sup>

The patients were divided into two groups; CT abnormality and no CT abnormality according to their Lund-Mackay scores. The differences of sino-nasal symptoms between groups were evaluated. Correlations between Lund-Mackay scores and SNOT-22 scores of patients with chronic rhinosinusitis were explored.

The statistical analysis was performed using STATA version 14 (STATA Corp., Texas, USA). The results were summarized using median (Interquartile range, IQR) for non-normally distributed continuous variables and number or percentage for categorical variables. The intraclass correlation coefficient (ICC) was used to assess inter-rater reliability of Lund-Mackay scores. The exact probability test was used to compare of the differences between categorical variables while the Mann-Whitney U test was used in non-normally distributed continuous variables. Correlation between Lund-Mackay score and SNOT-22 score was analyzed using Spearman's rank correlation. A *P*-value of less than 0.05 was considered to be statistically significant.

## Results

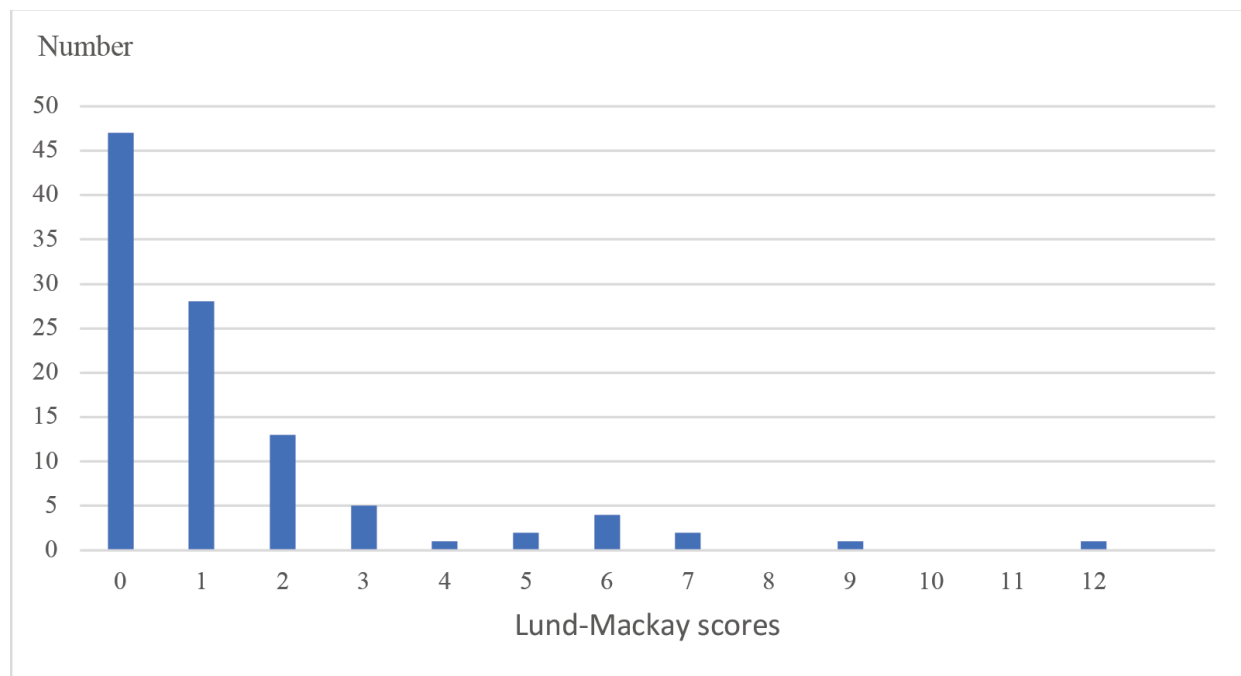
A total of 106 adults were initially enrolled in this study. Two patients were excluded due to skull fracture. The remaining 104 patients consisted of 57 (54.8%) men and 47 (45.2%) women, and their median age was 67 years (IQR 59 - 76, range

30 to 91). The most common indications for CT brain were suspected stroke (45.2%), followed by post intracranial hemorrhage (17.3%), and headache (10.6%).

A perfect inter-rater reliability of Lund-Mackay scores was found between the 2 imaging reviewers. The average measure ICC was 0.942 with a 95% confidence interval from 0.914 - 0.960 ( $P < 0.001$ ). The median Lund-Mackay score was 1 (IQR 0 - 2, range 0 to 12). The incidence rate of sinus mucosal abnormalities (score  $\geq 4$ ) was 10.6%. There were 47 (45.2%) patients with Lund-Mackay score of 0 and 46 (44.2%) patients with Lund-Mackay score of 1 - 3. Figure 1 shows the distribution of Lund-Mackay scores of all patients. The most common sinus abnormality was maxillary sinus (41.3% of patients), followed by anterior ethmoid sinus (19.2%), posterior ethmoid sinus (15.4%), sphenoid sinus (10.6%), frontal sinus (8.7%), and ostiomeatal complex (1.9%) as shows in Table 1.

According to Lund-Mackay score, we compared the sino-nasal symptoms and clinical diagnosis of rhinosinusitis of patients with and without CT abnormalities, or sinus mucosal abnormalities, as shows in Table 2. Among 11 patients who had abnormal CT findings, 9 (81.8%) patients had no sino-nasal symptoms, and 1 (9.1%) patient was suspected of having rhinosinusitis. Among 93 patients who had normal CT finding, 72 (77.4%) patients had no sino-nasal symptoms, and 9 (9.7%) patients were suspected of having rhinosinusitis. There were no significant differences in sex, age, sino-nasal symptoms or diagnosis of rhinosinusitis between the two groups.

There were 23 patients who had sino-nasal symptoms and only 10 patients were suspected of having rhinosinusitis. Eight out of ten patients who had had symptoms for more than 3 months were suspected of having chronic rhinosinusitis and were requested to complete the SNOT-22. There was no statistically significant correlation between Lund-Mackay score and SNOT-22 score ( $r = -0.18$ ,  $P = 0.657$ ).



**Figure 1** Distribution of Lund-Mackay scores.

**Table 1** Distribution of sinus abnormalities as indicated by LM scores

Area of sinuses	Laterality		Number of patients (n = 104)	%
	Unilateral	Bilateral		
Maxillary	27	16	43	41.3
Anterior ethmoids	15	5	20	19.2
Posterior ethmoids	12	4	16	15.4
Sphenoid	8	3	11	10.6
Frontal	8	1	9	8.7
Ostiomeatal complex	1	1	2	1.9

**Table 2** Comparison between patients with and without CT abnormality based on Lund-Mackay scores

Variables	Total (n = 104)	CT abnormality (n = 11)	No CT abnormality (n = 93)	P-value*
Sex: male	57 (54.8)	8 (72.7)	49 (52.7)	.337
Age, median (IQR), years	67 (59,76)	66 (58,74)	71 (63,78)	.267
No sino-nasal symptom	81 (77.9)	9 (81.8)	72 (77.4)	1.000
Rhinorrhea	15 (14.4)	2 (18.2)	13 (14.0)	.658
Nasal obstruction	10 (9.6)	0 (0.0)	10 (10.8)	.595
Facial pain	5 (4.8)	1 (9.1)	4 (4.3)	.435
Loss of smell	8 (7.7)	0 (0.0)	8 (8.6)	.595
Diagnosis of rhinosinusitis	10 (9.6)	1 (9.1)	9 (9.7)	.000

Abbreviation: IQR, interquartile range.

\*The exact probability test for categorical variables and Mann-Whitney U test for age.

## Discussion

In this study, we demonstrate the prevalence of incidental findings which were suspected to be rhinosinusitis in non-sinus related CT brain. Several studies have reported the frequency of sinus abnormalities on CT scans. Havas et al.<sup>2</sup> revealed sinus abnormalities in one or more of the paranasal sinuses in 42.5% of CT scans in asymptomatic adults. Nazri et al.<sup>1</sup> reported that the prevalence of sinus abnormalities is between 14.6% and 37.5% depending on the cut-off of the Lund-Mackay score. In our study, the prevalence of incidental sinus abnormalities was 54.8% and 10.6% at the cut-off values of  $\geq 1$  and  $\geq 4$ , respectively.

At present, the Lund-Mackay CT staging system is the most widely used,<sup>15</sup> but the normal scores and the relation with disease severity are problematic. Ashraf et al.<sup>8</sup> demonstrated that the Lund-Mackay score in the general population was not 0 and that the mean Lund-Mackay score was 4.26. The accuracy of CT in the diagnosis of CRS using Lund-Mackay scores was also tested. Assuming cut-off value of  $\geq 2$  as abnormal, the CT showed sensitivity and specificity of 94% and 41%, respectively. Increasing the cut-off value to 4 changed the sensitivity and specificity to 85% and 59%, respectively. The ROC method in conjunction with positive and negative predictive value analysis indicates Lund-Mackay scores  $\geq 4$  highly likely to represent true CRS.<sup>14</sup> And also, many studies have concluded that Lund-Mackay scores  $\leq 3$  are normal.<sup>1, 8, 16</sup> Thus, we defined sinus abnormality by a Lund-Mackay score which was  $\geq 4$ . The prevalence of incidental sinus abnormalities was 10.6% in our study, which was lower than in other reports. The difference is probably because we investigated non-sinus related patients at non-Ear, Nose and Throat (ENT) clinic.

In addition, we found that the Lund-Mackay score for each sinus may be excessive as a result of how the score is given. Each sinus is graded separately as clear, partially opaque or totally opaque but there are no standard percentages of opacification or mucosal thickening measurement to differentiate between each score. Any mucosal lesion is considered abnormal and generates a Lund-Mackay score of at least 1 for that sinus.<sup>8</sup>

Both maxillary sinus and ethmoid sinus have been reported to have higher prevalence of sinus abnormalities.<sup>2</sup> Our study shows that the most

frequently affected sinus is the maxillary sinus, followed by ethmoid sinus, which is the same result as those in many previous studies.<sup>15, 16</sup>

Most studies conclude that clinical symptoms are not always correlated with CT findings.<sup>17</sup> However, symptomatic sinus patients are much more likely to have positive sinus CT findings than asymptomatic patients.<sup>18</sup> In contrast, we report that the symptomatic patients have insignificantly lower prevalence of abnormal CT finding than the asymptomatic patients (8.7% vs. 11.1%,  $P = 1.000$ ). This is most likely because the symptoms of patients with chronic rhinosinusitis can be nonspecific and difficult to differentiate from other sino-nasal diseases. The common sino-nasal symptoms in our study are rhinorrhea (14.4%) and nasal obstruction (9.6%). Two subjects without any sino-nasal symptoms had Lund-Mackay scores 9 and 12. Therefore, consistent with most other studies, we found no definite correlation between incidental CT brain images and symptoms of rhinosinusitis.

There are some limitations in our study. Firstly, the sample size was too small to determine the association between CT images and sino-nasal symptoms. We included only subjects who were referred for CT brain with non-sinus related conditions and most of the subjects did not report any sino-nasal symptoms. Therefore, more patients are necessary for verifying our results. Secondly, we did not explore associated comorbidities or anatomical variations (e.g., concha bullosa, Haller cells, Onodi cells) which are important risk factors for rhinosinusitis and for abnormal sino-nasal structures that might miss interpretation with sinusitis. Thus, further study should be conducted in order to explain these limitations. Third, we did not assess nasal endoscopy concurrently with CT. Nasal endoscopy improves the sino-nasal evaluation by producing a closer visualization of the involved areas than is possible with anterior rhinoscopy.<sup>19, 20</sup>

In clinical implication, our study indicates that LM scores in asymptomatic adults are not 0 and that an LM score more than or equal to 4 should be recognized. While CT provides good information about paranasal sinus involvement, its relationship with symptoms is not reliable. Thus, CT should not be employed exclusively, but should be used concurrently with clinical symptoms for diagnosis of chronic rhinosinusitis.

### Acknowledgments

Financial support. No Author has a financial or proprietary interest in material or method mentioned.

Conflict of interest. All authors report no conflicts of interest relevant to this article.

### References

- Nazri M, Bux SI, Tengku-Kamalden TF, Ng KH, Sun Z. Incidental detection of sinus mucosal abnormalities on CT and MRI imaging of the head. *Quant Imaging Med Surg.* 2013;3(2):82-88.
- Havas TE, Motbey JA, Gullane PJ. Prevalence of incidental abnormalities on computed tomographic scans of the paranasal sinuses. *Arch Otolaryngol Head Neck Surg.* 1988;114(8):856-859.
- Smith-Bindman R, Kwan ML, Marlow EC, et al. Trends in Use of Medical Imaging in US Health Care Systems and in Ontario, Canada, 2000-2016. *JAMA.* 2019;322(9):843-856.
- Hansen AG, Helvik AS, Nordgard S, et al. Incidental findings in MRI of the paranasal sinuses in adults: a population-based study (HUNT MRI). *BMC Ear Nose Throat Disord.* 2014;14(1):13.
- Fokkens W, Lund V, Hopkins C, et al. European Position Paper on Rhinosinusitis and Nasal Polyps 2020. *Rhinology journal.* 2020;58:1-464.
- Zinreich SJ. Imaging for staging of rhinosinusitis. *Ann Otol Rhinol Laryngol Suppl.* 2004;193:19-23. doi:10.1186/1472-6815-14-13.
- Hopkins C, Browne JP, Slack R, Lund V, Brown P. The Lund-Mackay staging system for chronic rhinosinusitis: How is it used and what does it predict? *Otolaryngology-Head and Neck Surgery.* 2007;137(4):555-561.
- Ashraf N, Bhattacharyya N. Determination of the "Incidental" Lund Score for the Staging of Chronic Rhinosinusitis. *Otolaryngology-Head and Neck Surgery.* 2001;125(5):483-486.
- Bhattacharyya N. Clinical and symptom criteria for the accurate diagnosis of chronic rhinosinusitis. *Laryngoscope.* 2006;116(S110):1-22.
- Lumyongsatien J, Yangsakul W, Bunnag C, Hopkins C, Tantilipikorn P. Reliability and validity study of Sino-nasal outcome test 22 (Thai version) in chronic rhinosinusitis. *BMC Ear, Nose and Throat Disorders.* 2017;17:14.
- Hopkins C, Gillett S, Slack R, Lund VJ, Browne JP. Psychometric validity of the 22-item Sinonasal Outcome Test. *Clin Otolaryngol.* 2009;34(5):447-454.
- Morley AD, Sharp HR. A review of sinonasal outcome scoring systems - which is best? *Clin Otolaryngol.* 2006;31(2):103-109.
- Lund VJ, Mackay IS. Staging in rhinosinusitis. *Rhinology.* 1993;31(4):183-184.
- Bhattacharyya N, Fried MP. The accuracy of computed tomography in the diagnosis of chronic rhinosinusitis. *Laryngoscope.* 2003;113(1):125-129.
- Rathor A, Bhattacharjee A. Clinical-radiological correlation and role of computed tomography staging in chronic rhinosinusitis. *World J Otorhinolaryngol Head Neck Surg.* 2017;3(3):169-175.
- Sugiura S, Yasue M, Uchida Y, et al. Prevalence and Risk Factors of MRI Abnormality Which Was Suspected as Sinusitis in Japanese Middle-Aged and Elderly Community Dwellers. *BioMed Research International.* 2018;2018:4096845. doi:10.1155/2018/4096845.
- Stewart MG, Johnson RF. Chronic sinusitis: symptoms versus CT scan findings. *Current Opinion in Otolaryngology & Head and Neck Surgery.* 2004;12(1). doi:10.1097/00020840-200402000-00008.
- Wittkopf ML, Beddow PA, Russell PT, Duncavage JA, Becker SS. Revisiting the interpretation of positive sinus CT findings: A radiological and symptom-based review. *Otolaryngology-Head and Neck Surgery.* 2009;140(3):306-311.
- Shargorodsky J, Bhattacharyya N. What is the role of nasal endoscopy in the diagnosis of chronic rhinosinusitis? *The Laryngoscope.* 2013;123(1):4-6.
- Bhattacharyya N, Lee LN. Evaluating the diagnosis of chronic rhinosinusitis based on clinical guidelines and endoscopy. *Otolaryngology-Head and Neck Surgery.* 2010;143(1):147-151.